

Long-term Results of Cerebral Neurogenesis Stimulation with Transcatheter Intracerebral Low-level Laser (Light) Therapy for Alzheimer's Disease

Ivan V. Maksimovich, MD, PhD

Background:

The research is devoted to long-term results of cerebral neurogenesis after transcatheteric intracerebral Low-level Laser Therapy (LLLT) or Photobiomodulation therapy (PBMT) in Alzheimer's disease (AD) patients.

Materials & Methods:

220 patients with AD were examined. The examination included CDR definition, Tomography Dementia Rating scale (TDR), MMSE, cerebral CT, MRI, SG, rheoencephalography (REG), cerebral MUGA.

We selected 93 patients aged 34-80 (average age 67.5), 32 (34.40%) male, 61 (65.59%) female.

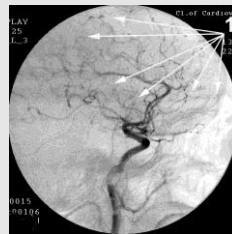
Test Group: Test Group, 48 (51.61%) patients: preclinical stage (TDR-0 dementia level) - 4 patients, early stage (TDR-1) - 16, middle stage (TDR-2) - 21, severe stage (TDR-3) - 7 patients. They all underwent transcatheter intracerebral LLLT (helium-neon laser).

Control Group: Control Group, 45 (48.39%) patients: preclinical stage (TDR-0 dementia level) - 6 patients, early stage (TDR-1) - 13, middle stage (TDR-2) - 15, severe stage (TDR-3) - 11 patients. These patients received conservative treatment (Memantine or Rivastigmine).

Results:

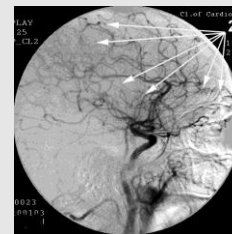
All 48 (100%) **Test Group** patients demonstrated improved microcirculation along with improved metabolism in neurons, neurogenesis and cerebral regenerative processes with 10–20% increase in cerebral temporal regions volume. The process was accompanied by decrease in dementia level and cognitive functions restoration, which made it possible to transfer the treated patients to a lighter stage TDR group. The resulting positive effect in TDR-0 and TDR-1 patients was observed for 10 years; in TDR-2 patients - 4-5 years; in TDR-3 patients - 2-2.5 years.

Control Group treatment resulted in a lack of neurogenesis, as well as in further increase in cerebral involutive changes and decrease in the volume of temporal lobes. In patients with early stages of AD (TDR-0, TDR-1), temporary stabilization of the condition was noted for 0.5 - 2 years followed by growing dementia and cognitive impairment. In patients with more severe stages of AD (TDR-2, TDR-3), further dementia and cognitive impairment growth was noted.

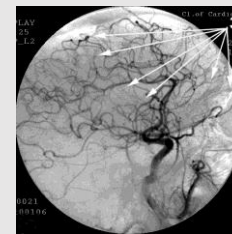


Patient T., 75 years old male (TDR-2). Prior to the transcatheter intracerebral LLLT (PBMT).

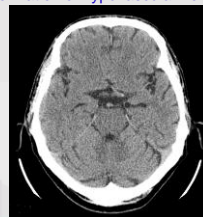
1. Reduction of the number of arterioles and capillaries in the temporal and frontal parietal areas with the formation of hypovascular zones.



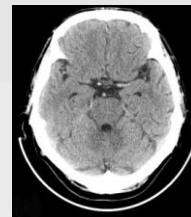
The same Patient T. After transcatheter intracerebral LLLT (PBMT).
 2. stimulation of angiogenesis, collateral and capillary bed recovery in temporal and frontoparietal region.



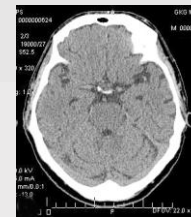
The same Patient T. 5 years after transcatheter intracerebral LLLT (PBMT).
 3. Progressing angiogenesis, collateral and capillary bed recovery in temporal and frontoparietal region.



The same Patient T. Prior to the transcatheter intracerebral LLLT (PBMT). Reduction of temporal lobes tissue mass: L-22%, R28%.



The same Patient T. 1 year after transcatheter intracerebral LLLT (PBMT). Reduction decrease: L-10%, R-12%.



The same Patient T. 5 year after transcatheter intracerebral LLLT (PBMT). Normalization of temporal lobes tissue mass.

Conclusions:

Transcatheter intracerebral PBMT (LLLT) is an effective treatment for AD. The method revascularizes the brain causing neurogenesis and restoration of tissue structures. The resulting effect persists for a long time causing dementia regression and cognitive functions restoration.